

# FieldStrength

Publication for the  
Philips MRI Community

**SPECIAL ISSUE | APRIL 2013**

## Intraoperative MR team focuses on patient care and productivity

Henry Ford Health System uses Achieva 1.5T in the midst of neurosurgery  
to help resect tumor and preserve normal brain



This article is part of FieldStrength issue ISMRM 2013

2013/1



**Steven N. Kalkanis, MD**, is Vice Chair, Department of Neurosurgery and Medical Director at Henry Ford Center for Cancer Surgery. In addition, he serves as President of the Michigan Association of Neurological Surgeons. He performed his Residency and fellowship training at Harvard-Massachusetts General Hospital (Boston, Massachusetts, USA). He has a special interest in brain tumors and diseases of the spine.

**Lisa Scarpace** is Clinical Coordinator iMRI, Henry Ford Hospital, Hermelin Brain Tumor Center. Her research interests include MRI Diffusion, Perfusion, and Spectroscopy use determining response to treatment and functional MRI use in surgical planning.

*“Monitoring the extent of resection is the biggest advantage to the MR-OR. With the immediate feedback of intraoperative MRI, we can make real-time adjustments when necessary.”*

## Intraoperative MR team focuses on patient care and productivity

**Henry Ford Health System uses Achieva 1.5T in the midst of neurosurgery to help resect tumor and preserve normal brain**

Henry Ford Health System (Detroit, Michigan, USA) is a quaternary care 1000-bed hospital. In February 2011, the hospital opened an MR operating room (MR-OR) including the Achieva 1.5T system, and it has quickly become a well run, highly productive practice.

The MR-OR system is used mainly for brain tumor surgeries, where it helps neurosurgeons to remove as much tumor as possible during surgery. In addition, the hospital's movement disorder neurosurgery team uses it for Deep Brain Stimulation placement for patients with Parkinson's disease and essential tremor. This procedure is done entirely within the MRI room, operating in the back of the magnet.

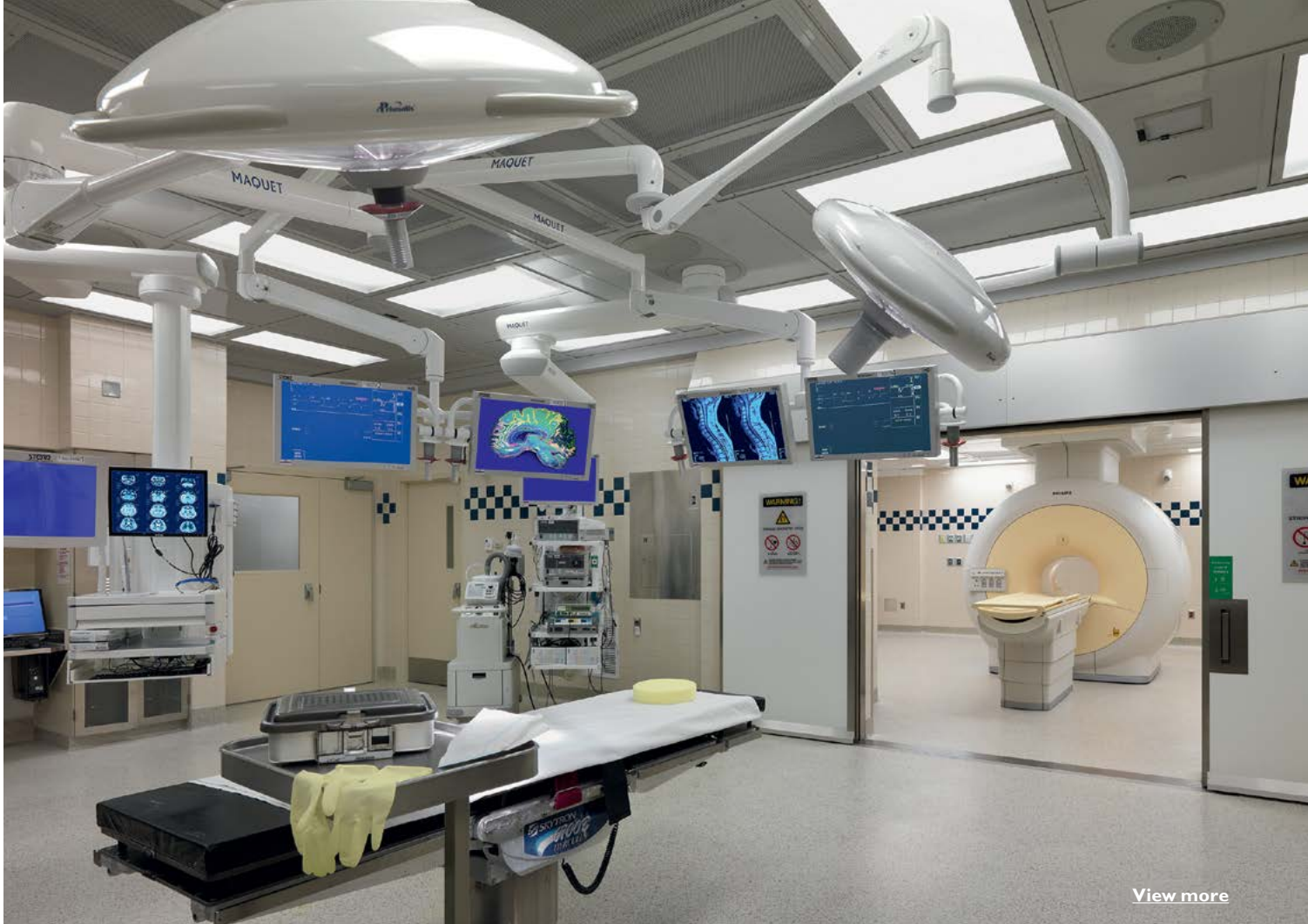When not needed for intraoperative imaging, the MR system is used as a diagnostic scanner, so it is essentially used around the clock, thanks to the dual-room setup. Approximately 4700 diagnostic scans have been performed on the system since installation, 140 of which have been intraoperative.

### **Team effort and planning come to fruition**

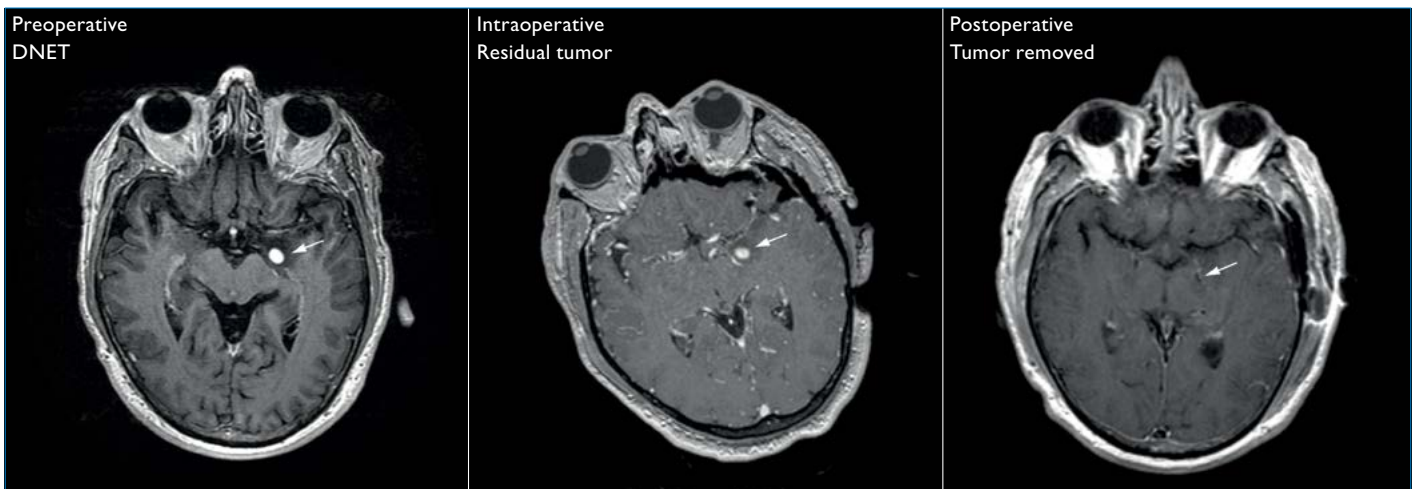
Steven Kalkanis, MD, says the implementation of the MR-OR solution was a multi-disciplinary team effort that took about a year in planning. “An essential initiative we undertook to ensure success was the concept of our team. We assembled an important team of neurosurgeons, anesthesiologists, radiologists, radiation physicists, nurses and scrub technicians, because this is not only a diagnostic scanner but an OR scanner.”

### **Major advantages for patient, neurosurgeon, hospital**

“Monitoring the extent of resection is the biggest advantage of the MR-OR,” says Dr. Kalkanis. “With the immediate feedback of intraoperative MRI, we can make real-time adjustments when necessary. That is very comforting, and it allows us to be more aggressive when it's appropriate.”



[View more](#)



### Gross total resection of brain tumor using intraoperative MRI

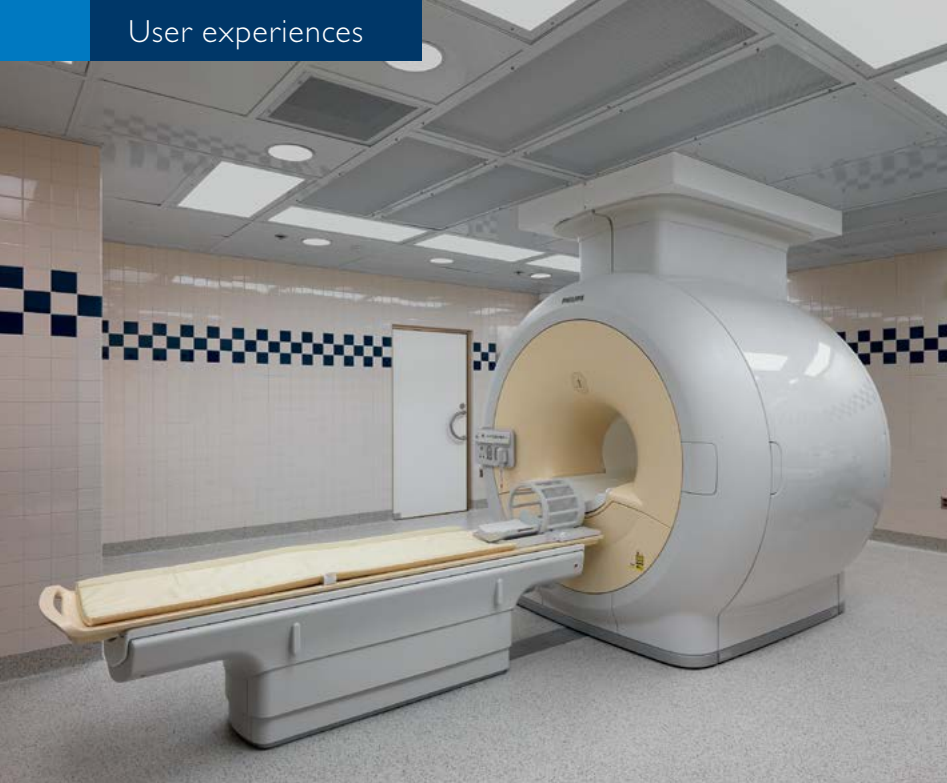A 64-year-old man presents with gustatory hallucinations and paresthesias for more than a year. Preoperative MR on the day of surgery shows a new focus of contrast enhancement in the medial left temporal lobe. Our surgeon used navigation to target this enhancement area and remove the abnormal tissue.

The intraoperative study showed the surgical tract extending from the left lateral temporal region up to the medial temporal tip. Post-contrast T1 images showed that the enhancing nodular tumor was just above and slightly posterior

to the medial tip of the surgical track. Postoperative imaging shows a complete resection of the left medial temporal lobe neoplasm. Pathological diagnosis was Dysembryoplastic Neuroepithelial Tumor (DNET). Intraoperative MRI showed the remaining tumor tissue which was essential to the success of this surgery.

Achieva 1.5T was used with Noras coil and integrated head holder frame. Standard imaging was done, T2, FLAIR, DWI, T1 and T1 post-contrast at contiguous thin cuts to load onto the Brainlab sky navigation system.

[CONTINUE](#)



## MR-OR at Henry Ford Health System\*

- Intraoperative MR adds 38 min. extra on average without complications, of which 22 min. is scan time.
- Extent of resection increased by >40% in more than half the cases
- In 75% of cases one intra-operative MRI is performed, in 25% a second.
- 140 intraoperative exams scanned in 2 years
- 4550 diagnostic MR exams in 2 years
- Currently 5 MR-OR procedures per week

\*These numbers may not be typical for all facilities

*“We basically use the MR-OR every day and we are currently figuring out how we can do more than one case in a day, because our demand has become so much greater.”*

The hospital benefits as well, by having a differentiator in a very competitive environment. Lisa Scarpace, Clinical Coordinator iMRI, says, “We’re doing leading-edge medical procedures very efficiently here. Patients are coming to us because we have the intraoperative MRI, and our results are really excellent because of it.”

### Start-to-finish simplicity

A typical MR-OR procedure is quite efficient. Less than 24 hours before the surgery, patients have a preoperative scan. “If the tumor enhances, we’ll do T1 non-contrast and T1 gadolinium scans to map it out,” explains Dr. Kalkanis. “If it’s a non-contrast enhancing tumor we’ll typically use a FLAIR or a T2 sequence.”

The patient comes to the OR with fiducial markers placed on the scalp. A preoperative scan is done to register the markers. Then an anesthetic is administered, and the patient is positioned in the head holder. “We then plan out our incision, make an incision in the scalp, remove a portion of the bone, and begin the resection. Soon, the tumor begins to look more normal along the margins. This is the critical step. Without the intraoperative MRI, most surgeons would stop at this point so as not to harm the patient and rely on radiation and chemotherapy afterward.”

“Instead, the patient is smoothly transferred into the MR scanner, and FLAIR, T2, DWI, T1 non-contrast and T1 post-contrast scans are performed. This takes about 20 or 25 minutes, and within minutes those images are being beamed back into the OR. And if there is tumor remaining, we can actually mark out on the image where our new target

is, and link the stereotactic wand to the new intraoperative MR scan that is pinpointing where the residual tumor is. We then remove any residual tumor, and close up.”

“In about 75% of cases we do one intraoperative scan; in the others we need more than one. We get a formal post-operative MRI scan the following day, and those generally show complete resection.”

“Possibly most remarkable is the short time needed for intraoperative MR scanning,” Dr. Kalkanis says. “In an internal study\* we found that our overall operative time was increased by only 38 minutes without any added complications, which includes about 22 minutes of scan time. The extent of resection was increased by over 40% in more than half the cases.”

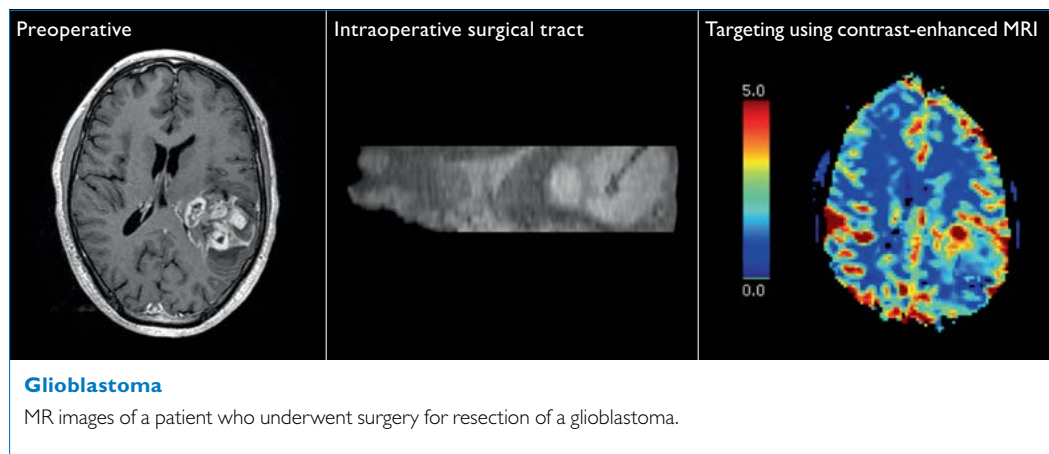
### Workflow

The Henry Ford team was worried that using the MR-OR system would add complexity and time to their cases, but Dr. Kalkanis says, “It became easier over time. Having people designated within each group as experts who are always there for every case makes all the difference in the world. Everyone knows his or her role in the overall structure, and it truly is routine. Every moment is accounted for, and it works out very well.”

“The way the MR-OR is configured adds to workflow efficiency,” he says. “It looks like a regular OR, but as soon as the sliding doors open, it’s immediately linked to the Achieva system. The beauty of this setup is that we haven’t changed our instruments in the OR, we haven’t changed our approach, we don’t stand in a different way.”



“Possibly most remarkable is the short time needed for intraoperative MR scanning.”



**Teamwork is the key to success**

Dr. Kalkanis points out the most important aspect of the project. “The biggest initiative we undertook to ensure success was the concept of our team. For every single patient, we include someone from each department.”

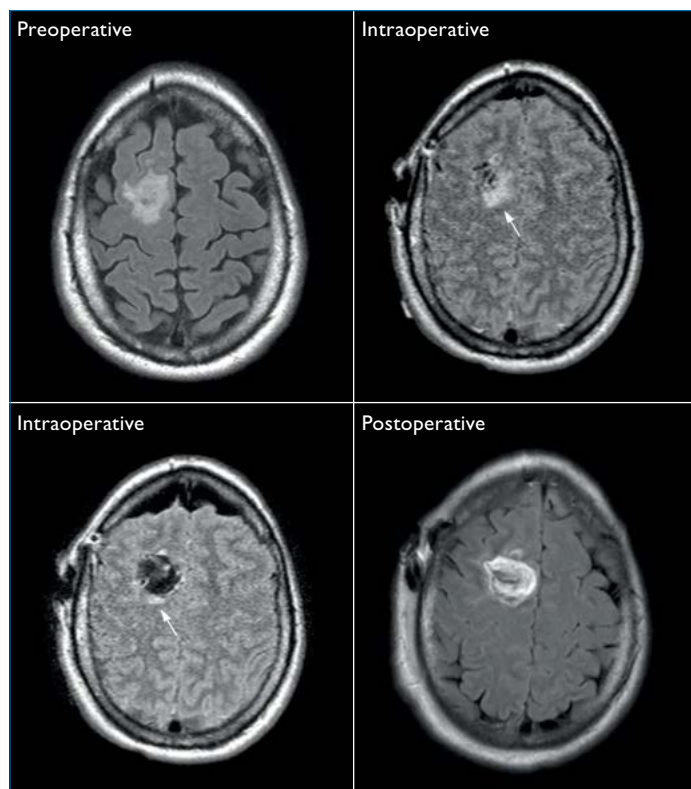
Lisa Scarpace emphasizes, “We had great training at the beginning. We had full OR staff (nurses, anesthesia and housekeeping), full radiology staff and all the surgeons there for three days. At first, everyone fought it, but in the end, that’s what made our team so cohesive.”

**The economic picture**

“We basically use the MR-OR every day,” says Lisa Scarpace. “And we are currently figuring out how to move things around so we can do more than one case in a day, because our demand has become so much greater.”

“For us, it’s a consideration of patient care,” she says. “When after surgery it turns out that a little bit of tumor is left, patients may need extensive radiation or chemotherapy, or sometimes a patient needs to be taken back to surgery a second time within the same week. MR-OR helps us monitor the extent of resection, that is a big advantage. Our surgeons are used to the system now, and they are confident that their patients will not need extensive radiation or chemotherapy.”

“Looking at the benefits of intraoperative MR and knowing that it only adds about a half hour of additional time, makes it an easy choice,” adds Dr. Kalkanis. ■



**Astrocytoma**

MR images of a patient who underwent surgery for resection of a newly diagnosed astrocytoma. The first intraoperative MRI shows residual tumor (arrow). The second intraoperative MRI shows minimal residual tumor. Postoperative MRI shows gross total resection of tumor.

**Reference**

CR Wirtz, M Knauth, A Staubert, MM Bonsanto, K Sartor, S Kunze, VM Tronnier  
*Clinical evaluation and follow-up results for intraoperative magnetic resonance imaging in neurosurgery*  
 Neurosurgery 2000 May;46(5):1112-20; discussion 1120-2